



Case Report

Bullous pemphigoid after second dose of mRNA- (Pfizer-BioNTech) Covid-19 vaccine: A case report

Fouad Alshammari^a, Yacoub Abuzied^b, Abdulrahman Korairi^c, Mohammed Alajlan^d,
Mohammed Alzomia^e, Mohammed AlSheef^{c,*}

^a Medical Resident, Medical Specialties Department, King Fahad Medical City, Riyadh, Saudi Arabia

^b Head Nurse, Spinal Cord Injury Unit, Rehabilitation Hospital, King Fahad Medical City, Riyadh, Saudi Arabia

^c Internal Medicine Consultant, Medical Specialties Department, King Fahad Medical City, Riyadh, Saudi Arabia

^d Dermatology Consultant, Medical Specialties Department, King Fahad Medical City, Riyadh, Saudi Arabia

^e Medical Intern, College of Medicine, King Saud University for Health Sciences, Riyadh, Saudi Arabia

ARTICLE INFO

Keywords:

Bullous pemphigoid
mRNA vaccine
Pfizer-BioNTech
Vaccine
Covid-19

ABSTRACT

Introduction and importance: Messenger RNA vaccines, commonly known as mRNA vaccines, are the first COVID-19 vaccines that have been authorized and licensed in the United States. Two mRNA vaccines, BNT162b2 (Pfizer-BioNTech) and mRNA-1273 (Moderna) are available. Mass vaccination remains the most critical way to halt the spread of the COVID pandemic. The most common adverse effects of the COVID vaccines are headache, muscular soreness, weariness, redness, swelling, and tenderness at the injection site. The dermatological adverse effects of mRNA vaccines, on the other hand, are little understood. We present a case of bullous fixed medication eruption following delivery of the second dose of Pfizer's Covid-19 vaccination.

Case presentation: We discuss the case of a 78-year-old man who went to the Emergency Department at King Fahad Medical City in Riyadh, Saudi Arabia, with numerous bullae throughout his extremities one day after receiving the second dosage of Pfizer Covid-19 vaccine. The bullae began three days before his presentation, and they were preceded by intense pruritus and urticated plaques. A skin biopsy was performed which revealed IgG (+1), IgM (+1), and C3 (+1) staining of the basement membrane. Another punch skin biopsy taken from an intact bulla was suboptimal compressing of dermal tissue only, revealing modest perivascular lymphocytic infiltrative and scattered eosinophils. This pathological picture with superficial perivascular inflammatory dermatitis, and the presence of eosinophils suggests drug-induced bullous pemphigoid. The patient was treated with topical and systemic corticosteroids, fusidic acid cream, and emollients after a confirmed diagnosis of bullous pemphigoid was obtained. He was hospitalized for 3 weeks as a case of severe sepsis due to a skin infection, and he was started initially on empiric antibiotics with piperacillin-tazobactam plus vancomycin that was later upgraded to meropenem and vancomycin based on the results of the blood and wound cultures. The patient suffered a pulmonary embolism on the second day of hospitalization and was placed on a heparin infusion that could potentially contribute to his death one month after discharge from our hospital.

Clinical discussion: Bullous pemphigoid is the most frequent autoimmune bullous disease. It occurs in the elderly. The cause of this disease is unknown, although it sometimes can be triggered by taking certain medications. Two case reports have also revealed bullous pemphigoid eruption following immunization. One case report reported a 78-year-old lady with diabetes and Alzheimer's disease who developed tense bullae on her face and torso after getting the second dosage of the Pfizer-BioNTech COVID-19 Vaccine. Another case study described a 77-year-old male patient who developed generalized pruritus and bullae on erythematous bases one day after receiving the AstraZeneca COVID-19 vaccination. This new-onset bullous pemphigoid phenomenon has also been observed with other vaccinations such as rabies and swine flu.

Conclusion: Although uncommon, several dermatological side reactions like bullous eruptions have been reported following the mRNA Pfizer Covid-19 vaccination. According to this case report, Bullous pemphigoid might be caused by the mRNA- (Pfizer) Covid-19 Vaccine.

* Corresponding author. Tel. +966544014035

E-mail addresses: ftalshammari@kfmc.med.sa (F. Alshammari), yabuzied2@gmail.com (Y. Abuzied), aakorairi@kfmc.med.sa (A. Korairi), malajlan@kfmc.med.sa (M. Alajlan), alzomiae427@outlook.com (M. Alzomia), malsheef@kfmc.med.sa (M. AlSheef).

<https://doi.org/10.1016/j.amsu.2022.103420>

Received 18 January 2022; Received in revised form 22 February 2022; Accepted 27 February 2022

Available online 1 March 2022

2049-0801/© 2022 The Authors. Published by Elsevier Ltd on behalf of IJS Publishing Group Ltd. This is an open access article under the CC BY-NC-ND license

(<http://creativecommons.org/licenses/by-nc-nd/4.0/>).

1. Introduction

In early December 2019, a novel coronavirus known as severe acute respiratory syndrome coronavirus-2 (SARS-CoV-2) developed in Wuhan, China, and was responsible for the global COVID-19 pandemic [1]. Atypical pneumonia symptoms such as fever, cough, and shortness of breath are typical of the condition [1]. Fatigue, a runny nose, a headache, myalgia, and anosmia are some of the other symptoms [1]. Even though numerous medications have been licensed by the FDA to treat COVID-19, mass vaccination remains the most critical way to halt the spread of the pandemic [2]. COVID-19 vaccines are available in a variety of forms, including nucleic acid, inactivated virus, live-attenuated virus, and recombinant protein, and are either licensed for use or still in clinical studies [2].

Messenger RNA vaccines, commonly known as mRNA vaccines, are the first COVID-19 vaccines that have been authorized and licensed in the United States. Two mRNA vaccines, BNT162b2 (Pfizer-BioNTech) and mRNA-1273 (Moderna) encode for S protein, which facilitates receptor recognition and viral entry within human cells [2]. For a successful immunogenic response, mRNA entry and translation inside the cytoplasm are required [3]. This reaction is characterized by the activation of T-helper cells and the generation of antibodies [3]. Headache, muscular soreness, weariness, redness, swelling, and tenderness at the injection site are the most typical adverse effects of the COVID-19 vaccinations [4]. The dermatological adverse effects of mRNA vaccines, on the other hand, are little understood. We present a case of bullous fixed medication eruption following delivery of the second dose of Pfizer's Covid-19 vaccination. This case report has been reported in line with the SCARE 2020 criteria [5]. The research registration unique identifying number (UIN) is researchregistry7670 <https://www.researchregistry.com/browse-the-registry#home/>

2. Case presentation

A 78-year-old man with diabetes, hypertension, and chronic renal disease reported to the Emergency Department with several bullae across his extremities (Fig. 1A). The bullae appeared three days ago, following intense pruritus and urticated plaques one day after getting the second dose of the Pfizer Covid-19 vaccine. Our patient had no adverse effects on the first dosage, which was given 21 days before the second dose. Nonetheless, the second dosage was eventful, with urticated plaques appearing one day after the immunization and being followed by several varying size bullae (Fig. 1B). There was no evidence

of mucous membrane involvement. Initial laboratory test results showed leukocytosis with a neutrophilic predominance and a normal platelet count (See Table 1). The patient was treated with topical corticosteroids, fusidic acid cream, and emollients after a preliminary diagnosis of bullous pemphigoid was obtained. Figures illustrate the remarkable response following three days of topical steroids and emollients treatment (Fig. 2). Three weeks later, he returned to the dermatologist outpatient clinic for a check-up. The patient complained of generalized irritation and the appearance of fresh pruritus all over his body. A skin biopsy was performed, and prednisolone 20mg once daily was begun on an impromptu basis. The skin biopsy revealed IgG (+1), IgM (+1), and C3 (+1) staining of the basement membrane (Fig. 3A). The other punch skin biopsy taken from an intact bulla was suboptimal compressing of dermal tissue only (Fig. 3B). Shows a poor skin sample that compresses only the dermal tissue, revealing modest perivascular lymphocytic infiltrative and scattered eosinophils. This pathological picture with superficial perivascular inflammatory dermatitis, and the presence of eosinophils suggests drug-induced bullous pemphigoid. His son took him to the Emergency Department again twenty days after the clinic appointment, this time with a lowered degree of awareness and subjective temperature.

The patient was hypotensive, tachypneic, tachycardic, and febrile (38° Celsius). He was given 2L of standard intravenous saline as well as additional oxygen. On physical examination, there were numerous diffuse erosions, post-inflammatory hyper and hypopigmentation, and crusting (Fig. 4A&B). There were no new blisters or original skin lesions discovered. A laboratory examination revealed a white blood count of 17.2 with a neutrophilic preponderance. He was hospitalized as a case of severe sepsis due to a skin infection, and he began empiric treatment with piperacillin-tazobactam plus vancomycin. Blood and wound cultures grew extended-spectrum beta-lactamase *Escherichia coli* and Methicillin-resistant *Staphylococcus aureus* (MRSA), respectively, according to the septic workup. As a result, antibiotics were increased to meropenem and vancomycin. The patient suffered a pulmonary embolism on the second day of hospitalization and was placed on a heparin infusion. He was admitted to the hospital for three weeks to finish the necessary course of antibiotics. He was discharged home after 25 days of prednisolone 20mg daily treatment with a spectacular clinical response, as seen in the statistics (4). Then after one month from discharge patient was found to have died in his bed of an unknown cause but it could be attributed to pulmonary embolism.

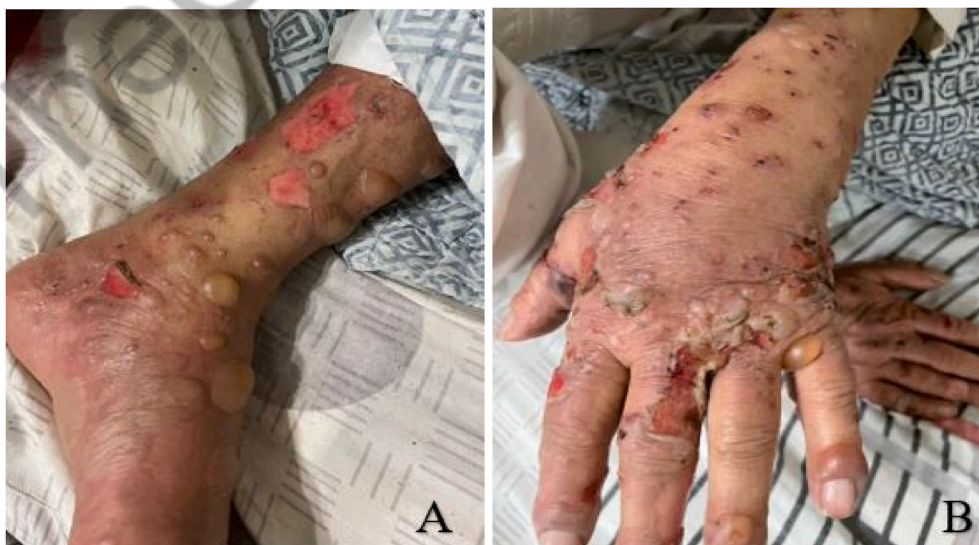

Fig. 1. (A&B): Clinical Picture of multiple intact bullae of variable sizes with ruptured bullae and erosions.

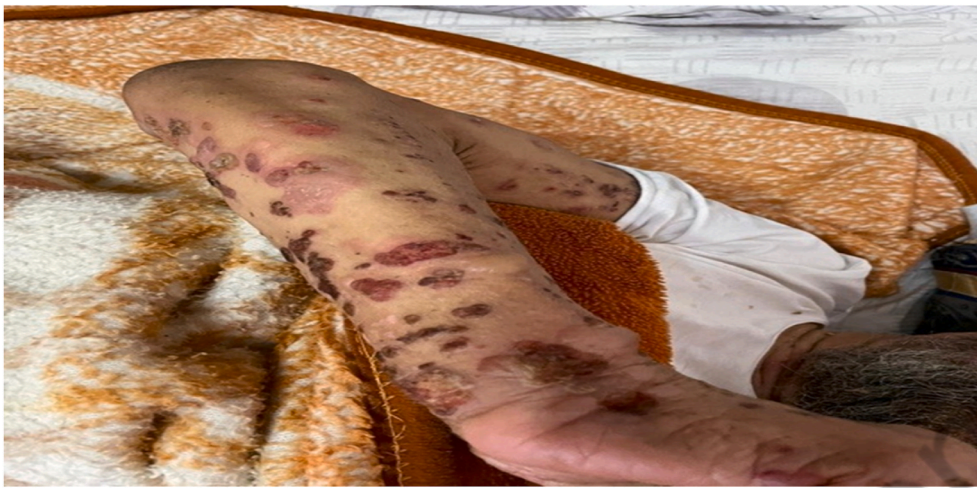

Fig. 2. The significant response after three days of topical steroids.

Table 1
Laboratory results.

Laboratory results		Reference range
White cell count (10e9/L)	19.9	3.9–11
Neutrophils (%)	86.5	30–70
Lymphocytes (%)	8.00	23–60
Absolute Neutrophil count (10e9/L)	17.25	1.35–7.5
Absolute Lymphocyte Count (10e9/L)	1.59	1.5–4.3
Hemoglobin (g/dL)	15.00	11–16
Platelets count (10e9/L)	247	155–435
PT (Prothrombin Time) (S)	17.400	9.7 0 12.6
APTT (S)	28.300	25.3–38.3
INR	1.46	0.81–1.23
Fibrinogen (g/L)	0.39	1.61–4.39
Troponin (ng/L)	6.3	0–15.6
Lactate (mmol/L)	3.5	0.5–2.2
D-Dimer (µg/mL)	128	0–0.5
Lactate Dehydrogenase (U/L)	904	125–220
Ferritin (ng/mL)	883	10–204
C Reactive Protein(mg/L)	109	1–3
ALT (U/L)	60	0–55
AST (U/L)	92	5–34
Alkaline Phosphatase (U/L)	79	40–150
Total bilirubin (umol/L)	14	3–20
Creatine Kinase (U/L)	3473	30–200
Creatinine umol/L	68	64–104
Potassium (mmol/L)	5.1	3.5–4.5
Corrected Calcium (mmol/L)	2.21	2.1–2.55
Phosphate (umol/L)	0.96	0.74–1.52
Magnesium (mmol/L)	0.80	0.66–1.07

3. Clinical discussion

Bullous pemphigoid is a rare autoimmune dermatological disorder that primarily affects the elderly beyond the age of 60. The cause of this disease is unknown, although it sometimes can be triggered by taking certain medications. Itching is frequently the first symptom, followed by urticarial lesions and, finally, blisters. Numerous cutaneous abnormalities, most typically local site injection responses, have been described with mRNA COVID-19 vaccinations [4]. Morbilliform eruption, urticaria, Pernio-like lesions, and vasculitis are some uncommon cutaneous symptoms that have been reported too [6]. Two case reports have also revealed bullous pemphigoid eruption following immunization. One case report reported a 78-year-old lady with diabetes and Alzheimer's disease who developed tense bullae on her face and torso after getting the second dosage of the Pfizer-BioNTech COVID-19 Vaccine [7] Another case study described a 77-year-old male patient who developed generalized pruritis and bullae on erythematous bases one day after

receiving the AstraZeneca COVID-19 vaccination [8]. This new-onset bullous pemphigoid phenomenon has also been observed with other vaccinations such as rabies and swine flu [9,10].

COVID-19 patients may also have cutaneous symptoms. Morbilliform rash, pernio-like acral lesions, urticaria, macular erythema, vesicular eruption, papulosquamous eruption, and retiform purpura were the most often reported signs in a 716-patient worldwide registry [11]. Other autoimmune problems have been observed following the injection of COVID-19 vaccinations. For example, vaccine-associated immune thrombosis and thrombocytopenia (VITT) is now a well-known adverse effect of the COVID-19 vaccine, especially the AstraZeneca vaccine [12]. Guillain-Barré syndrome (GBS) is another autoimmune disorder that has been linked to an unfavorable event [13]. COVID-19 patients may also have other non-cutaneous autoimmune problems such as hemophagocytic syndrome, Kawasaki disease in children and adults, myositis, arthritis, myocarditis, neurological and renal immune-related manifestations [14].

4. Conclusion

- Bullous pemphigoid is the most frequent autoimmune bullous disease. It occurs in the elderly. The cause of this disease is unknown, although it sometimes can be triggered by taking certain medications and vaccines. According to this case report, Bullous pemphigoid might be caused by the mRNA- (Pfizer) Covid-19 Vaccine. Additional case reports are required to learn more about this disease to achieve early diagnosis and initiation of prompt therapy.

Ethical approval

The approval of the ethics committee was not necessary for the publication. However, the patients' written agreement to publish their clinical data was obtained and is accessible for review by the handling editor if necessary. And an IRB was obtained from King Fahad Medical City, Riyadh, Saudi Arabia.

Sources of funding

This case study received no particular financing from funding bodies in the public, commercial, or non-profit sectors.

Author contribution

The study team created and supervised the design and production of the case report, as well as data extraction, analysis, and a systematic

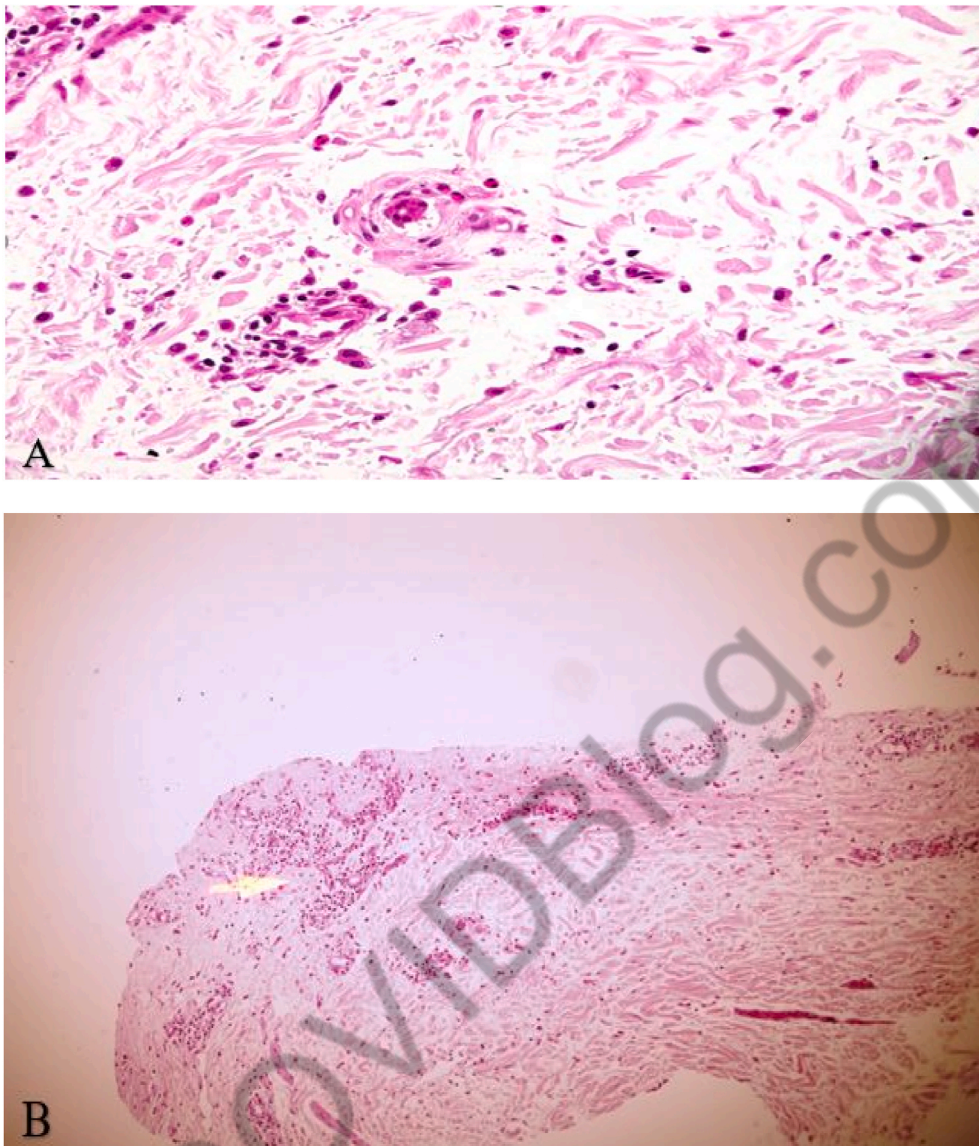


Fig. 3. (A&B): Microscopic pictures.

Skin biopsy compressing of dermal tissue only, showing superficial perivascular inflammatory dermatitis and with prominent eosinophils would be suggestive of a drug eruption.

assessment of the literature for data retrieval. All authors reviewed and approved the final version of this paper. Before submission, all of the mentioned authors approved the case report, including the names, data, and graphics. All of the writers provided feedback and helped shape the case report.

Research registration

Name of the registry: Research Registry.

Unique Identifying number or registration ID: researchregistry7670.

Hyperlink to your specific registration (must be publicly accessible and will be checked): <https://www.researchregistry.com/browse-the-registry#home/>

Guarantor

Dr. Mohammed Alsheef.

Consent

Written informed consent for publication of this case and any accompanying images was obtained from the patient. A copy of the written consent is available for review by the Editor-in-Chief of this Journal.

Provenance and peer review

Not commissioned, externally peer-reviewed.

Declaration of competing interest

The authors state that they have no conflicts of interest for this report.

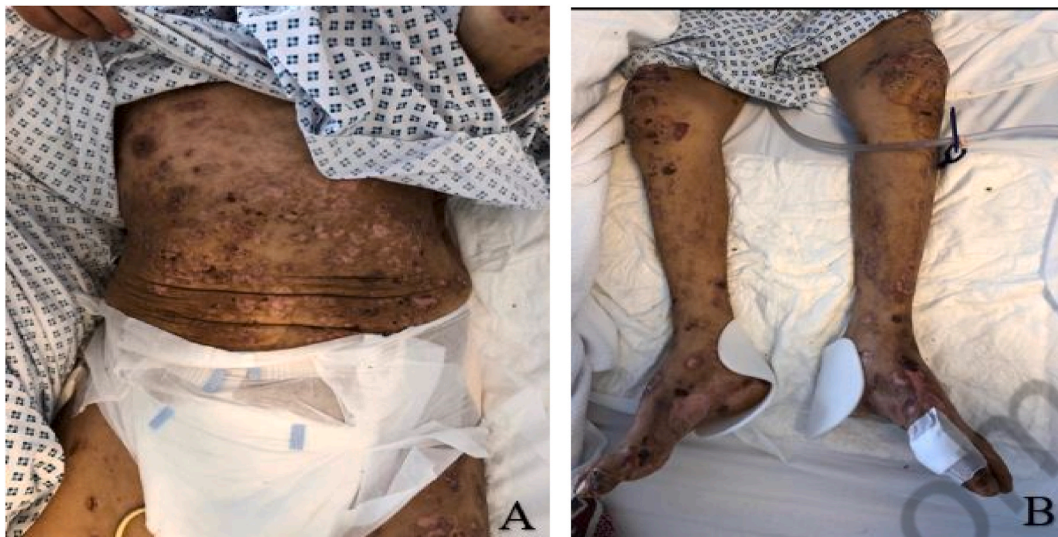

Fig. 4. (A&B): (21 days post Steroid): Clinical Picture of the patient 21 days after the systemic steroid initiation showing excellent improvement with no new bullae in addition to multiple healed erosions, post-inflammatory hyper-, and hypopigmentations.

Acknowledgments

The authors would like to thank the research center at King Fahad Medical City in Riyadh, Saudi Arabia, for their assistance and technical support.

We are thankful to Dr. Mohammed Ameen (Pathology Consultant at King Fahad Medical City) for his kind assistance and cooperation in collecting the patient's pathology figures.

Appendix A. Supplementary data

Supplementary data to this article can be found online at <https://doi.org/10.1016/j.amsu.2022.103420>.

References

- [1] N. Chams, S. Chams, R. Badran, A. Shams, A. Araj, M. Raad, S. Mukhopadhyay, E. Stroberg, E. Duval, L. Barton, I. Hajj Hussein, COVID-19: a multidisciplinary review, *Front. Public Health* 8 (2020).
- [2] J. Chung, M. Thone, Y. Kwon, COVID-19 vaccines: the status and perspectives in delivery points of view, *Adv. Drug Deliv. Rev.* 170 (2021) 1–25.
- [3] Q. He, Q. Mao, J. Zhang, L. Bian, F. Gao, J. Wang, M. Xu, Z. Liang, COVID-19 vaccines: current understanding on immunogenicity, safety, and further considerations, *Front. Immunol.* 12 (2021).
- [4] C. Menni, K. Klaser, A. May, L. Polidori, J. Capdevila, P. Louca, C. Sudre, L. Nguyen, D. Drew, J. Merino, C. Hu, S. Selvachandran, M. Antonelli, B. Murray, L. Canas, E. Molteni, M. Graham, M. Modat, A. Joshi, M. Mangino, A. Hammers, A. Goodman, A. Chan, J. Wolf, C. Steves, A. Valdes, S. Ourselin, T. Spector, Vaccine side-effects and SARS-CoV-2 infection after vaccination in users of the COVID Symptom Study app in the UK: a prospective observational study, *Lancet Infect. Dis.* 21 (7) (2021) 939–949.
- [5] R.A. Agha, T. Franchi, C. Sohrabi, G. Mathew, for the SCARE Group, The SCARE 2020 guideline: updating consensus surgical CASE REport (SCARE) guidelines, *Int. J. Surg.* 84 (2020) 226–230.
- [6] D. McMahon, E. Amerson, M. Rosenbach, J. Lipoff, D. Moustafa, A. Tyagi, S. Desai, L. French, H. Lim, B. Thiers, G. Hruza, K. Blumenthal, L. Fox, E. Freeman, Cutaneous reactions reported after Moderna and Pfizer COVID-19 vaccination: a registry-based study of 414 cases, *J. Am. Acad. Dermatol.* 85 (1) (2021) 46–55.
- [7] I. Pérez-López, D. Moyano-Bueno, R. Ruiz-Villaverde, Bullous pemphigoid and COVID-19 vaccine, *Med. Clínica* 157 (10) (2021) e333–e334.
- [8] F. Agharbi, M. Eljazouly, G. Basri, M. Faik, A. Benkirane, A. Albouzi, S. Chiheb, Bullous Pemphigoid Induced by the AstraZeneca COVID-19 Vaccine, *Annales de Dermatologie et de Vénérologie*, 2021.
- [9] S. Nayak, A. Jindal, S. Shenoi, R. Rao, V. Monappa, Bullous pemphigoid triggered by rabies vaccine, *Indian J. Dermatol., Venereol. Leprol.* 86 (1) (2020) 66.
- [10] N. Walmsley, P. Hampton, Bullous pemphigoid triggered by swine flu vaccination: case report and review of vaccine triggered pemphigoid, *J. Dermatol. Case Rep.* 5 (4) (2011).
- [11] E. Freeman, D. McMahon, J. Lipoff, M. Rosenbach, C. Kovarik, S. Desai, J. Harp, J. Takeshita, L. French, H. Lim, B. Thiers, G. Hruza, L. Fox, The spectrum of COVID-19-associated dermatologic manifestations: an international registry of 716 patients from 31 countries, *J. Am. Acad. Dermatol.* 83 (4) (2020) 1118–1129.
- [12] M. Franchini, G. Liunbruno, M. Pezzo, COVID-19 vaccine-associated immune thrombosis and thrombocytopenia (VITT): diagnostic and therapeutic recommendations for a new syndrome, *Eur. J. Haematol.* 107 (2) (2021) 173–180.
- [13] L. Arce Gálvez, L. Ramírez Abadía, C. de los Reyes Guevara, J. Hernández Orozco, Guillain-Barre syndrome after vaccination for Covid-19. The first report in Latin America, *Neurol. Perspect.* 1 (4) (2021) 236–238.
- [14] M. Ramos-Casals, P. Brito-Zerón, X. Mariette, Systemic and organ-specific immune-related manifestations of COVID-19, *Nat. Rev. Rheumatol.* 17 (2021) 315–332, <https://doi.org/10.1038/s41584-021-00608-z>.